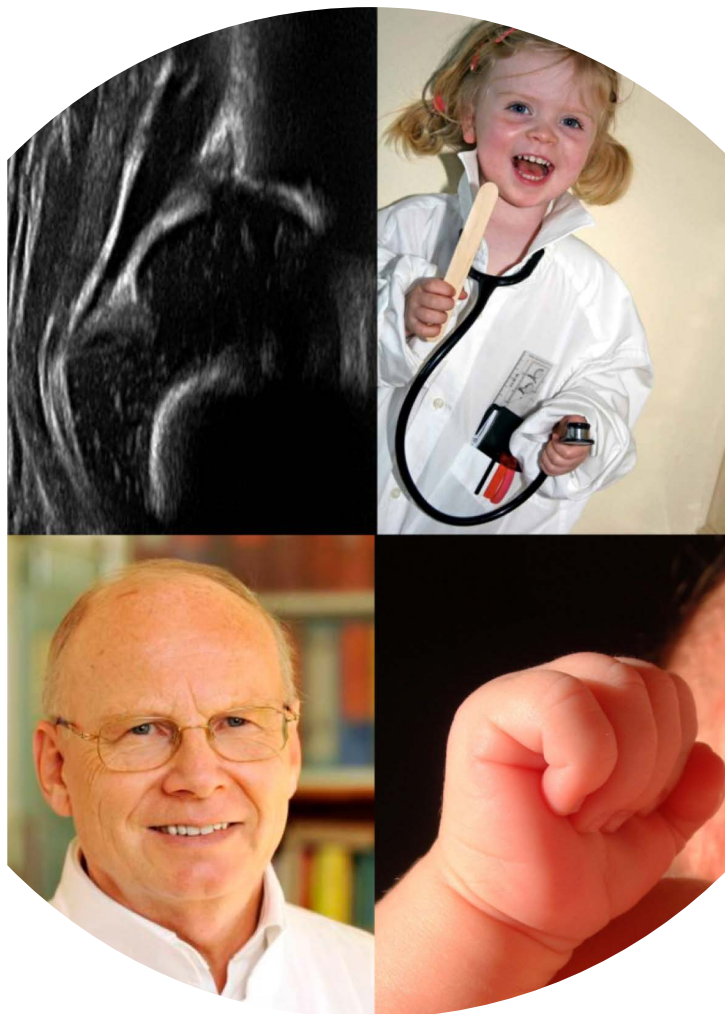



# ESSENTIALS OF INFANT HIP SONOGRAPHY

## According to GRAF



**R. Graf**

**K. Lercher**

**S. Scott**

**T. Spieß**



Authors:	R. Graf	A-8850 Murau, Hagersiedlung 7
	K. Lercher	A-8852 Stolzalpe
	S. Scott	Merton Grange BH 11 9QJ
	T. Spieß	A-8852 Stolzalpe

Edition Stolzalpe Sonocenter 2017, A-8852 Solzalpe

## Introduction

One of the main causes of misdiagnosis in infant hip sonography is the errors that occur due to poor quality hip ultrasound resulting from the deterioration in teaching standards whereby formal courses in hip sonography have been replaced in many centres by informal “bedside teaching”. Errors creep in and are perpetuated, gaining cult status.

This manual is intended to give guidelines for both the instructor and the student. It provides a step-by-step teaching programme with regular checks of what has been learnt.

The manual includes only the basics, emphasizing the essential facts. The scientific background can be found in the referenced literature (see page 35).

**R. Graf**

## The three pillars of hip sonography are:

- A) Examination Technique
- B) Anatomical Identification ( Checklist 1)
- C) Usability Check ( Checklist 2)

### 1. Anatomy/Anatomical Identification

Sound knowledge of the anatomy of the infant hip joint as seen on ultrasound is essential so that errors in diagnosis, resulting from incorrect identification of structures on the ultrasound image, can be avoided.

#### 1.1 Chondro-Osseous Border (ChB)

The proximal femur and femoral head are mainly formed of hyaline cartilage. The ChB separates the hyaline part from the bony part.

The hyaline parts are:

**Femoral head**

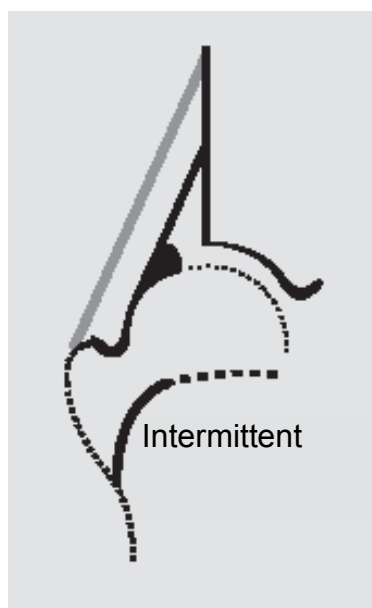
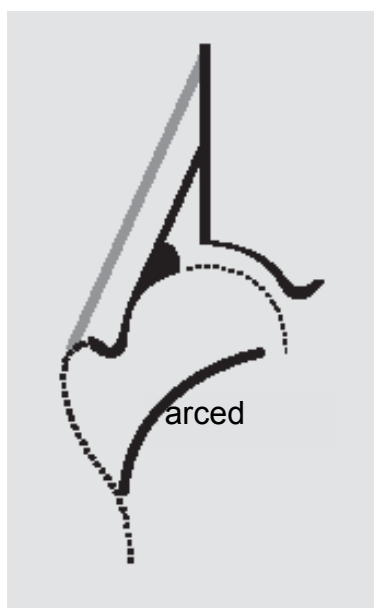
**Greater trochanter**

**Proximal part of the femoral neck**

The echoes from the ChB are the most important landmark from which to identify all the other anatomical structures.

The ChB takes 3 basic forms:

- **Arced** in neonates.
- **Palisades**; the medial section of ChB is seen as intermittent parallel echoes.
- **Medial section missing**; medial part is obscured by the acoustic shadow of the lateral part.

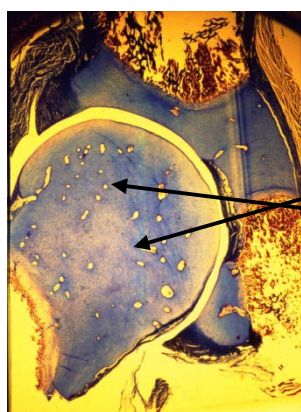


## 1.2 Femoral Head

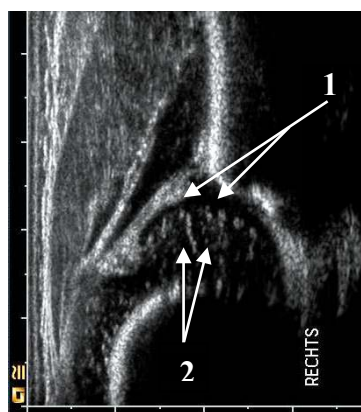
The neonatal femoral head is not round like a ball but is nutlike or slightly oval. From a geometric point of view the baby hip joint corresponds more to an oval joint with physiological incongruity and is never like a ball bearing.

The central part of the hyaline head contains “vessels” (sinusoids).

Sonographically these are seen as worm or comma like reflections. These echoes are only visible in the central area (central zone) whereas the superficial area (annular zone) is almost devoid of vessels and in a sonogram appears as an echo free ring. This anechoic zone should not be mistaken for an effusion or fluid.



Sinusoids



1. Annular Zone

2. Central Zone

### Femoral Head Nucleus

The nucleus of the femoral head is not usually in the centre. Therefore, the femoral head nucleus on ultrasound should never ever be used, as it is on an X ray, to assess the relationship between the head and socket

The nucleus is seen 4-8 weeks earlier on a sonogram than on an X ray.

This is due to the early condensation of cells that occurs prior to ossification being visible on ultrasound.

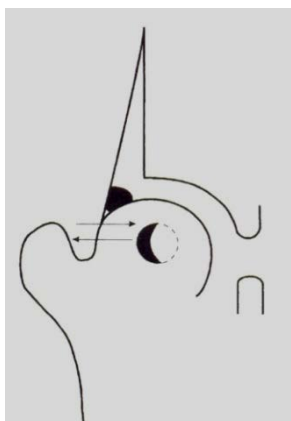
If the ossification of the hip joint is so far advanced that the nucleus is large and blocks the penetration of sound waves so that the lower limb of the Ilium is in the acoustic shadow, then sonography cannot be used for diagnosis (see usability check).

#### Problems with femoral head nucleus:

- **Size assessment**
- **Half moon phenomenon**
- **Diagnostic error**
- **Limiting the method**

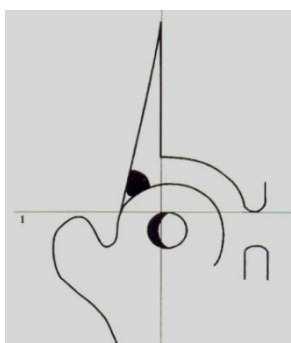
#### SIZE ASSESSMENT:

As the nucleus is not the centre of the femoral head and is not round, it is possible that most of the nucleus lies outside the ultrasound plane. Therefore, reproducible evaluation of the size of the nucleus by sonography is impossible.



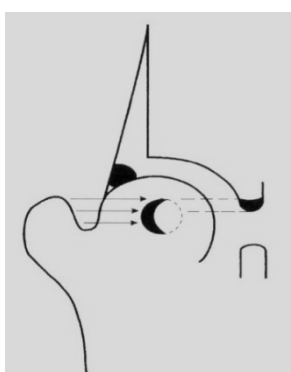
### HALF MOON PHENOMENON:

With a large femoral head nucleus, only the lateral part is seen since the medial part lies in the acoustic shadow.



### DIAGNOSTIC ERROR:

The femoral head nucleus is not usually the centre of the femoral head. Due to the half moon phenomenon, the nucleus mistakenly appears to lie laterally.



### LIMITING THE USE OF ULTRASOUND:

When the lower limb of the ilium is obscured by the acoustic shadow of a large femoral head nucleus and is not visible, hip sonography cannot be used for diagnosis.

(One exception: See usability check).

## 1.3 Synovial Fold

The capsule of the hip joint encloses the femoral neck and merges, in the region of the zona orbicularis, into the perichondrium of the greater trochanter. This turning point where the capsule goes to the perichondrium of the greater trochanter is called in hip sonography the “*synovial fold*”. Its echo appears either as a rounded spot or as two parallel stripes.

The *synovial fold* must not be mistaken for the labrum.

## 1.4 Hip Joint Capsule

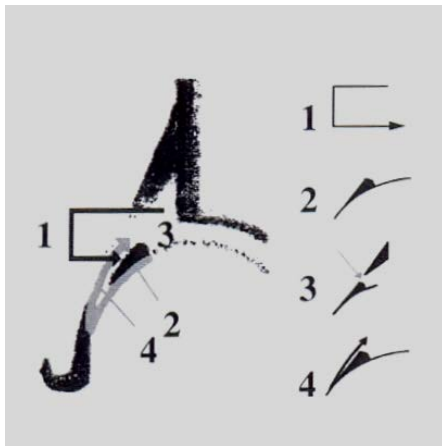
The femoral head is enclosed laterally by the capsule. From the *synovial fold* the joint capsule can be followed cranially over the femoral head and then over the cartilage portion of the acetabular roof. The capsular echo ends in fatty tissue under the reflex head of the rectus femoris muscle.

When starting from the synovial fold and following the joint capsule, it is essential not to follow an intermuscular septum by mistake. Starting from the synovial fold on the sonogram, always follow the most medial echo cranially, not the lateral one. The ischio femoral ligament is a bright echo within the proximal capsule and must not be mistaken for the labrum.

**1.5 Acetabular Labrum**

Follow the capsule on the surface of the femoral head cranially and the acetabular labrum will be found lying adjacent to and inside the capsule. The fibro-cartilaginous labrum is seen as an echogenic triangular structure inside the joint. It is attached to the lateral portion of the hyaline cartilage roof.

Sonographically it is sometimes difficult to clearly locate the position of the acetabular labrum. In order to identify it, four (4) definitions are helpful.




1. The labrum is always the echo found lateral and distal to the anechoic hyaline cartilage roof inside the joint capsule.
2. The labrum is always in contact with the femoral head.
3. The labrum is always situated caudal to the perichondrial gap.
4. The labrum is located where the contour of the capsule diverges from the surface of the femoral head.

All four definitions do not need to be used. It is adequate if the labrum can be clearly identified using a single definition.

**Standard Sequence**

After identification of the acetabular labrum, follow the surface of the femoral head from lateral to medial and the next structure, adjacent to the labrum, is the hyaline cartilage roof. Medial to this the echoes from the bony roof are seen.



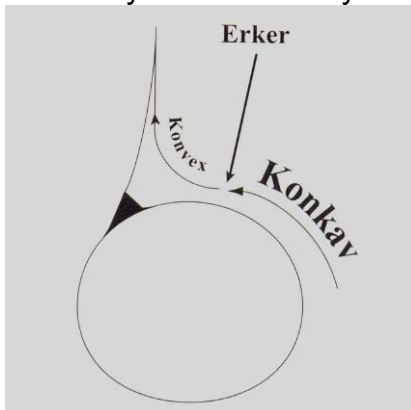
- Abridged: 1. Labrum  
2. Cartilage  
3. Bony Roof**

The purpose of the “Standard Sequence” is to ensure that the cartilage roof is identified and not forgotten.

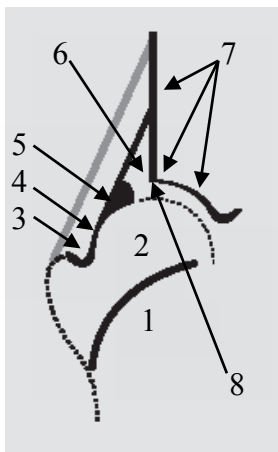
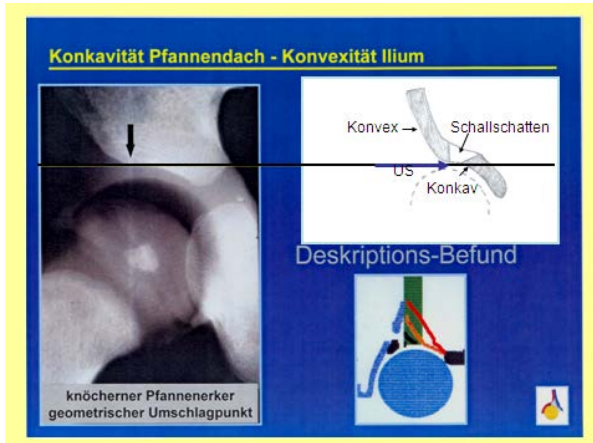
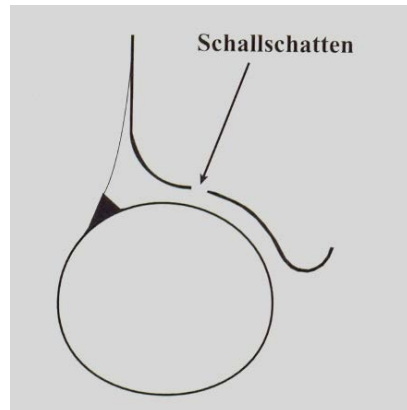
### 1.6. Definition of the Turning Point/Bony Rim

The bony rim is the most lateral point of the concave bony socket. Briefly the bony rim is the turning point from **concavity to convexity**. It is essential to look for the turning point from inner to outer i.e. distal medial to proximal lateral. There is frequently a small acoustic shadow just medial to the turning point/bony rim. The bony rim is the lateral point of the sound shadow.

Concavity/Rim/Convexity



Acoustic Shadow



#### Checklist 1: Anatomical Identification

1. ChB
2. Femoral Head
3. Synovial Fold
4. Joint Capsule
5. Labrum
6. Cartilage
7. Bony Roof
8. Bony Rim (Turning Point)



When evaluating a sonogram, all the anatomical structures (Checklist 1) must be identified in the correct order. Even if **only one structure is missing** the sonogram is not diagnostic and **must not be used**.

### 1.7 Perichondrium:

The perichondrium is the lateral border of the hyaline cartilage roof.

Proximally it merges into the periostium of the iliac bone; distally it merges into the capsule of the joint.

The distal portion of the perichondrium is rather thin and gives only a few or hardly any echoes.

In hip sonography it is therefore called the “*perichondrial gap*”.

The proximal perichondrium is relatively thick and gives strong echoes. It is called the “*proximal perichondrium*”.

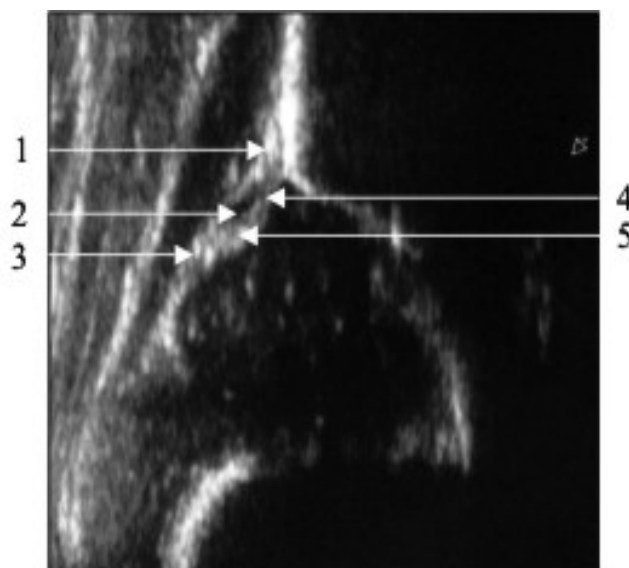
**The terms “perichondrial gap” and “proximal perichondrium” are only used in hip sonography.**

Both terms define precise anatomical structures which can be seen with high resolution ultrasound.

Proximal Perichondrium is a composite of echoes comprised of the rectus femoris tendon (reflex head), the fat deposit of the joint capsule, and the perichondrium of the cartilage roof.

### Perichondrial Gap

Differing impedance results in strong echoes from the proximal rectus tendon and ischio-femoral ligament; and faint echoes from the more distal capsule and perichondrium.



- 1) Rectus Femoris Tendon (Reflex Head)
- 2) Fat deposit at the end of the capsule
- 3) Ischio Femoral Ligament
- 4) Perichondrium of the hyaline-cartilage roof
- 5) Acetabular Labrum

## 2. Usability Check

In order for hip sonograms to be comparable, it is necessary to establish a standardised cross section of the hip joint. A cross section needs three coordinates (landmarks).

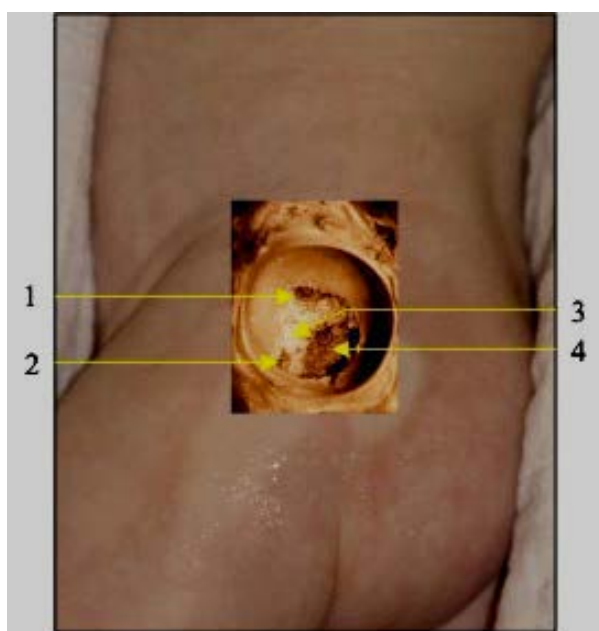
### 2.1 Lower Limb of Ilium

The lower limb of the Ilium is the portion of the bone that lies in the acetabular fossa. It is not covered by the lunate fascia. Sonographically the lower limb is a strong echo in the middle of the acetabulum. It is more or less the centre of the acetabulum and thus is the rotation axis for planes through the bony roof.

The depth of the acetabular fossa consists of 3 bones:

**Lower limb of the Iliac bone**  
**Pubic bone**  
**Ischial bone**

The 3 bones are joined by the triradiate cartilage.



1. Lower Limb of the Iliac Bone
2. Pubic Bone
3. Triradiate Cartilage
4. Ischial Bone

During the sonographic examination, the lower limb of the Ilium (centre of the joint) must always be looked for first. If the lower limb of the Ilium is missing on the sonogram, the picture produced must not be used for making a diagnosis as the cross section does not pass through the centre of the joint.

### **NO CURE WITH HIP SONOGRAPHY WITHOUT A LOWER LIMB**

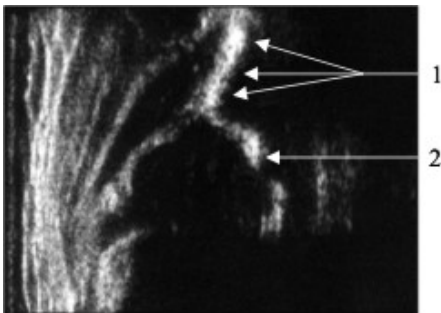
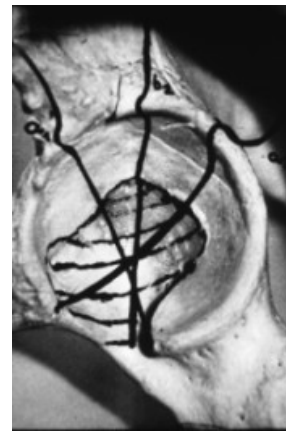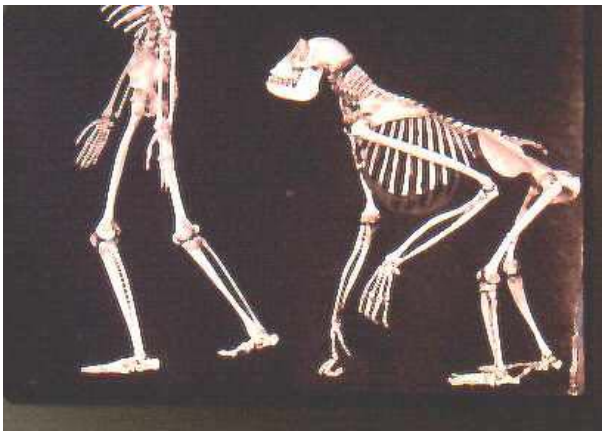
**EXCEPTION:** In decentred joints the lower limb of the Ilium may not be visible as the femoral head dislocates posteriorly and cranially and thus may move out of the standard plane.

## 2.2 Cross Sections

For reasons which can be illustrated by our evolution from walking on all fours to the upright position (pelvic rotation), the posterior portion of the bony acetabulum is better developed than the mid and anterior portions.

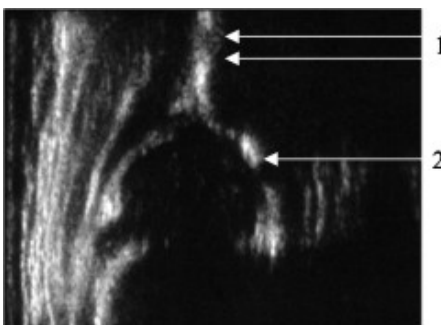
In order to identify sonographically whether the bony roof has been cut in the anterior, mid or posterior sectional plane, it is most important to find the lower limb of the Ilium first. When comparing the sections through the bony roof in the same hip joint, one finds that the posterior section is better developed and covers the femoral head more than the mid or anterior sections.

As the mid portion of the bony roof represents the weight bearing zone, especially in the upright position, the mid section is taken as a compromise when classifying the bony roof.



The posterior section is identified by the trough-shaped silhouette of the iliac bone (concavity of the gluteal fossa).

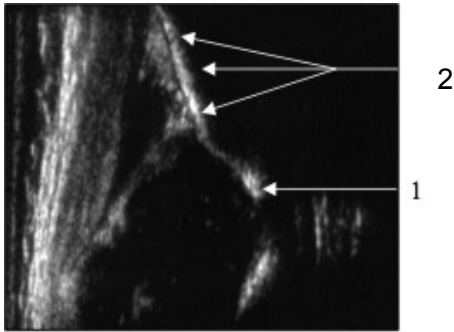
1. Posterior section (trough shaped silhouette of the iliac bone)
2. Lower limb of Ilium



In the mid cross section, the Iliac bone silhouette above the acetabulum is straight, parallel to the margin of the monitor.

The exact definition of the mid portion of the bony roof is that point where the iliac bone silhouette becomes straight when the transducer is rotated anteriorly from the posterior cross section.

1. Cross section of the mid bony roof (straight echo of Ilium)
2. Lower limb of Ilium



The **anterior section** is identified by the iliac bone silhouette inclining towards the transducer.

1. Lower limb of Ilium
2. Anterior cross section; Iliac bone silhouette inclined towards the transducer

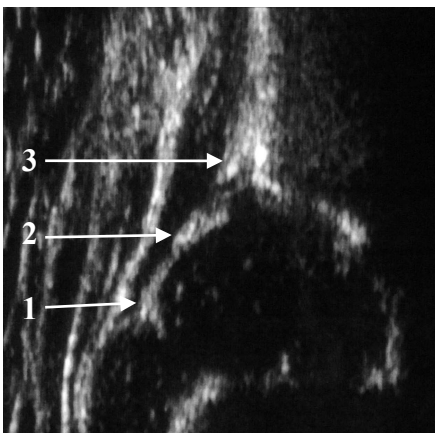
Sonographically only images taken in the mid sectional plane of the bony roof should be used for diagnosis.

Exception: In decentred joints which are dislocated postero-cranially, diagnosis is still possible. However, measurements must not be made (see later).

### 2.3 Labrum

If the lower limb of the Ilium and the mid sectional plane are correct, the labrum is always visible.

In decentred hips, it is sometimes difficult to see the labrum. However, with the help of the 4 definitions for finding the position of the labrum, it can always be located.



**On sonograms, the acetabular labrum is often mistaken for:**

- 1 Synovial Fold
- 2 Ischio-Femoral Ligament (the labrum is always the echo inside)
- 3 Proximal Perichondrium

### Summary:

A plane can only be defined if there are 3 landmarks.  
In hip sonograms, they are:

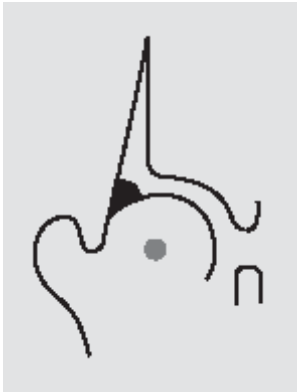1. Lower limb of the Ilium
2. Cross section through mid portion of the bony roof
3. Acetabular labrum

When these three landmarks are present on the sonogram, then this is the Standard Plane. Only sonograms that are in the Standard Plane can be measured.

### 3. Classification of Types

The sonographic classification is based on the pathological alterations in the hip joint and not on the height of the dislocation of the femoral head. The hip sonographic classification classifies the bony and cartilaginous roof correlated to the age.

#### 3.1 Type I:



The hip joint is fully mature.

Description: The bony socket is well developed (good), the region of the bony rim is angular or blunt, and the cartilage roof overlaps (covers) the femoral head. Type One (I) joints should be present by the end of the third (3) month.

The term “healthy hip joint” should no longer be used as a Type Two (II) joint can also be healthy. (IIa+)

A Type I joint remains a Type I joint unless:

Exceptions (acc. frequency):

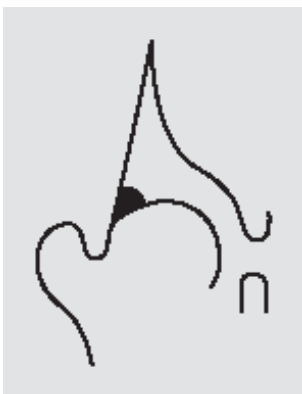1. Wrong initial diagnosis; it was never a Type I
2. Neuromuscular imbalance
3. Effusion (Distention luxation by coxitis)
4. Secondary dysplasia

In some decentred joints which were initially treated until they were Type I.

In these cases the epiphyseal plate may have been damaged by the shearing forces on the bony roof during luxation resulting in cessation of endochondral growth. Although initially primary “healing” has occurred during further growth, the ossification halts and secondary dysplasia sets in.

Treated joints must subsequently be followed up, until the end of growth.

#### 3.2 Type II :



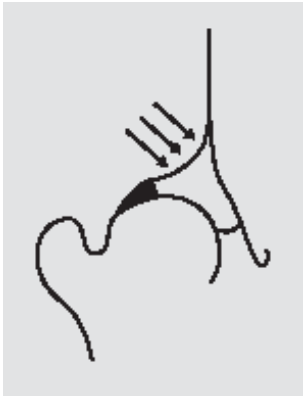This is also a centered joint: The total roof, bone plus cartilage, covers the femoral head well.

However, the proportions between the bone and cartilage differ from Type 1 with more cartilage and less bone.

Description: The cartilage roof is deficient (II a / II b) or adequate (II a +), the region of the bony rim is rounded and, in comparison, the cartilage roof appears larger, but overlaps (covers) the femoral head well.

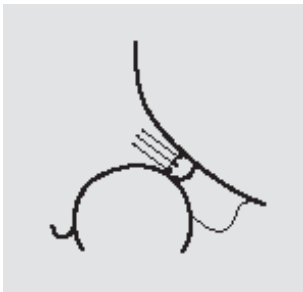(For the difference between “deficient” and “adequate”, see Chapter Five)

### 3.3 Type III: Decentred Joint

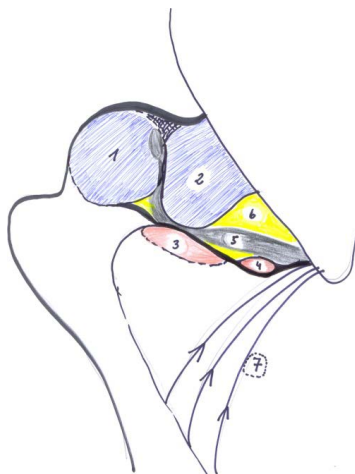


Description: The bony roof is poor; the region of the bony rim is flattened and the cartilage roof is displaced cranially. The femoral head has dislocated due to the poor bony socket and, during the course of luxation, has pushed most of the cartilage roof upwards, cranially. Only a small portion of cartilage roof is pressed downwards, caudally. Sonographically a decentred hip is seen to be a Type III if the perichondrium of the cartilage roof goes upwards, cranially, from the femoral head.

### 3.4 Type IV:



Also a decentred joint. In distinction from Type III, in Type IV the femoral head has displaced the cartilaginous roof completely downwards, caudally, towards the original socket. On the sonogram, the perichondrium runs horizontally or is trough-like (see arrows). No cartilage is seen above the femoral head.



#### Type IV Pathological Anatomy

- 1 Femoral Head
- 2 Cartilage
- 3 Iliopsoas
- 4 Transverse Ligament
- 5 Capital Femoral (Teres) Ligament
- 6 Fat
- 7 Adductors

In a sonogram, Type III and Type IV are not differentiated by the position of the acetabular labrum but by the course of the perichondrium. (Upwards Type III; horizontal or trough-like Type IV)

**Limbus:** The term “limbus” has no agreed definition and should not be used. The term limbus is sometimes used for the labrum. Sometimes, limbus is used to describe the labrum plus cartilage roof. Alternatively, limbus is used to describe only the cartilaginous roof because the cartilaginous portion which is pushed caudally has been described as the “neolimbus”. The term limbus cannot be safely assigned to any anatomical structure. It is only an obsolete historical term.

## 4. Standards of Reporting

### 4.1 Sonogram Format

- a) Name of patient
- b) Date of birth
- c) Side specified
- d) Two( 2) standard plane sonograms of each side
- e) One (1) sonogram per side with measurement lines.
- f) Scale of magnification 1.7:1

### 4.2 Standard Report

- a) Name
- b) Age
- c) Description with preliminary type
- d) Angle measurement, Alpha/Beta with final details of type
- e) Treatment consequences

## 5. Description

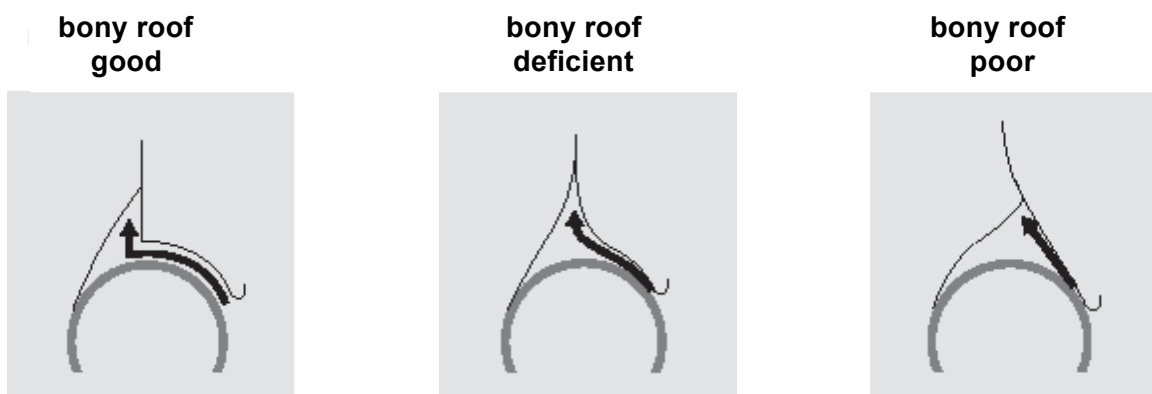
The description has lost importance with the current high standards. However, it should always be carried out so that the examiner is obliged to visually evaluate the bony and cartilaginous roof, helping to eliminate wrong diagnoses caused by incorrect angle measurements.

The main structures of the hip socket are described according to their importance. Standardised terms for this description have proved useful over the years.

The bony socket - the shape of the region of the bony rim and the cartilaginous roof are described.

### Bony roof:

Good – adequate/deficient - poor.



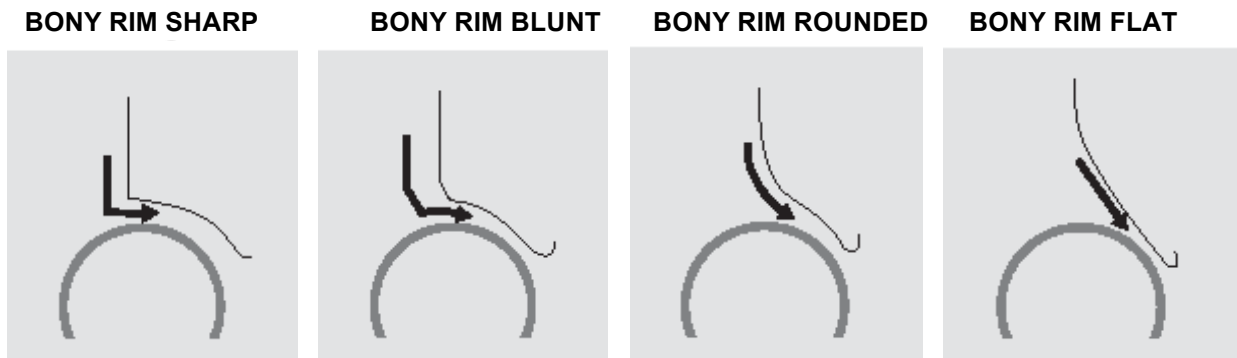
**Explanation of Terms**

**Deficient:** Refers to Type II joints with delayed maturity (delayed ossification). There is insufficient bony roof. (Pathology present).

**Adequate:** Refers to Type II joints with age-appropriate ossification and hip joint development which is physiologically immature but normal for age.

**Region of Bony Rim**

Sharp/blunt – rounded – flat



**Cartilaginous Roof:**

**Overlapping (COVERING):** This term is used for centered hips and signifies that the cartilaginous roof extends over the femoral head caudally and helps keep the femoral head in the socket.

**Displaced:** Is the synonym for a decentred hip joint; the femoral head has deformed the cartilaginous roof.

**Secondary Ossification:**

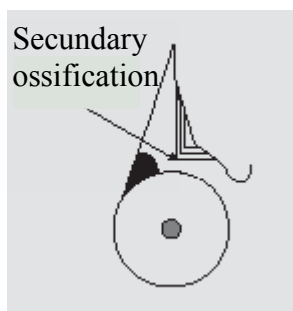
In Type II joints, the wide as yet unossified cartilage roof must finally ossify in order to become a Type I joint. This change of hyaline cartilage into bone proceeds in a similar manner to the ossification of the femoral head nucleus i.e. echoes become present in the hyaline cartilage adjacent to the bone consistent with early ossification.

These echoes are classified as “secondary ossification”.

As with the echogenicity of the femoral head nucleus, this process of secondary ossification is seen four to eight weeks earlier in a sonogram than in an X-ray.

*Therefore do not compare an X-ray and a sonogram from the same date.*

Secondary ossification gives as an angular silhouette to the region of the bony rim, even though the bony roof is still deficient or adequate.



Secondary ossification occurs only in centered hips.

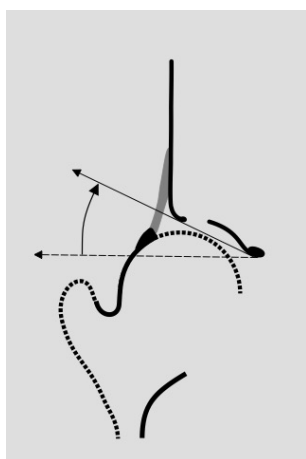


Type	Bony Roof	Bony Rim Region	Cartilage Roof
I	good	angular / blunt	covering
II	deficient / adequate	round	covering
III	poor	flat	displaced upwards
IV	poor	flat	displaced downwards
EXCEPTION Type II with ossification	deficient / adequate	angular	covering

## 6. Measurement Technique

Measurements must only be carried out in the Standard Plane.

### 6.1 Bony Roof Line



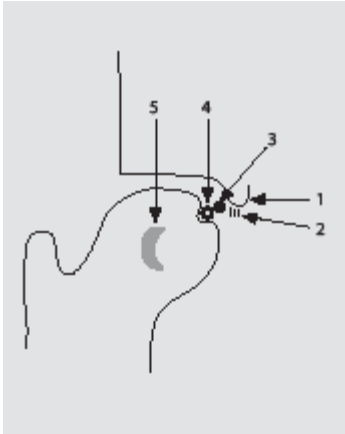
The lower limb of the Ilium is the pivot point. A tangent is placed laterally from the pivot point just touching the bony roof (not the bony rim).

The lower limb has to be clearly and accurately defined. To achieve this, the following anatomical points of reference are indispensable:

Caudal to the lower limb of the Ilium is the triradiate cartilage which is more or less an echo-free zone.

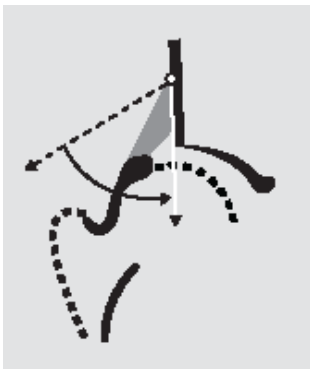
Echoes in the triradiate cartilage correspond to **vascular sinusoids**. These sometimes lie immediately caudal to the lower limb of the Ilium and should not be seen as part of the Ilium. Lateral to the lower limb **fat and interstitial tissue** line the **acetabular fossa**.

**Teres (Femoral Capital) Ligament:** This ligament has its origin in the acetabular incisure and ends in the central fovea of the femoral head.

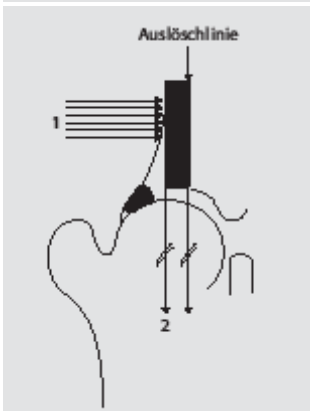


- 1. Lower limb Ilium
- 2. Sinusoids
- 3. Fatty tissue
- 4. Teres/capital femoral ligament
- 5. Femoral head nucleus

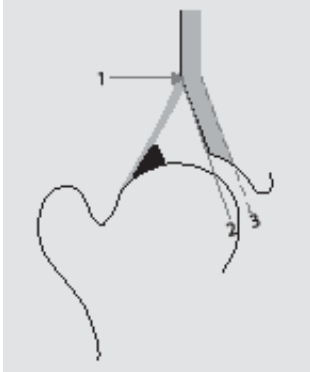
**6.2 Base Line**



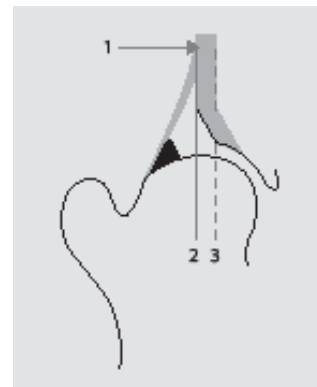
First the uppermost point of the cartilaginous roof must be sought. Sonographically it is the point where the echo of the proximal perichondrium meets with the echo from the Ilium. Anatomically it is the point where the rectus tendon inserts into the Ilium. From this pivot at the uppermost point of the cartilaginous roof, a tangent is placed cranial to caudal along the echo of the Ilium.



Auxiliary base line.  
If the ultrasound machine performs poorly, the uppermost pivot may not be identified precisely. A help in such cases is the ARTEFACT LINE or auxiliary help line.

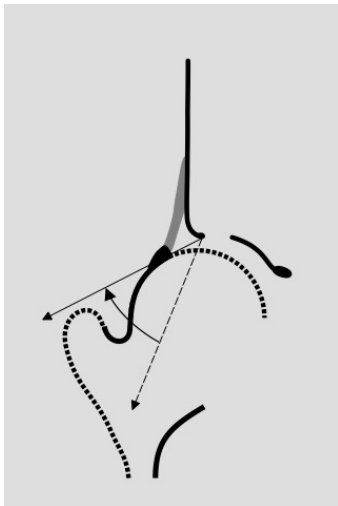


- 1 uppermost point
- 2 base line
- 3 auxiliary line



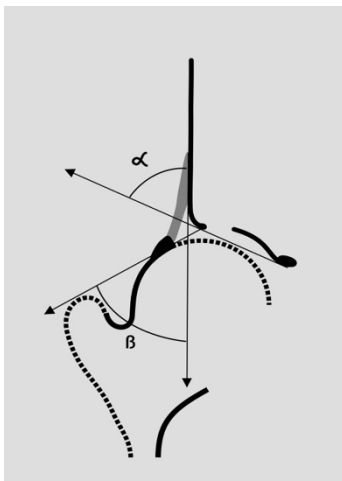
**The angle between the base line and bony roof line is the ALPHA angle.**

### 6.3 Cartilage Roof Line : (CRL)



The cartilage roof line is drawn from the turning point/bony rim (Concavity /Convexity) through the middle of the labrum. The middle of the labrum means its strongest echo.

**The cartilaginous roof line and base line form the BETA angle .**

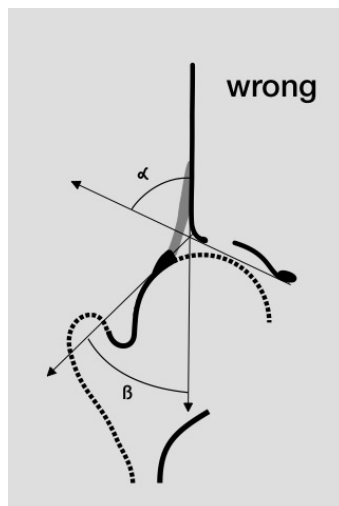
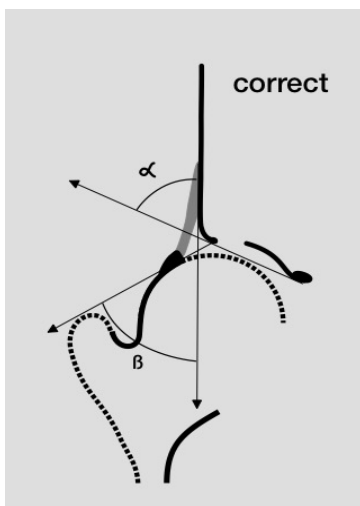


All three lines only have a common intersection if the bony rim is angular.

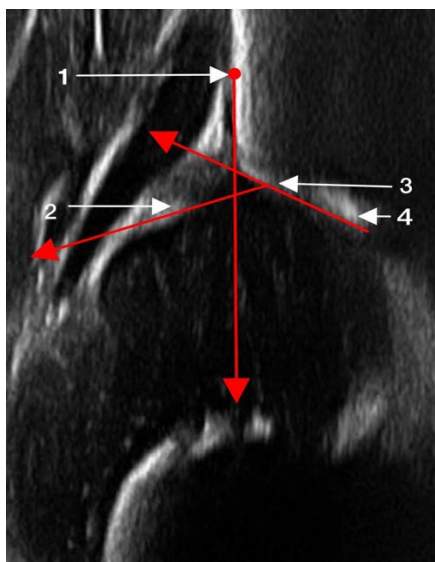
The base line and bony roof line form the bony angle ALPHA. Alpha evaluates the size of the bony socket.

The base line and cartilaginous roof line form the BETA angle. Beta evaluates the size of the cartilaginous roof.

**The three lines seldom cross at one point!**



If all three lines do converge at one point, the bony rim has probably been wrongly identified.



- 1. Uppermost point of cartilaginous roof
- 2. Acetabular labrum
- 3. Bony rim
- 4. Lower limb of Ilium

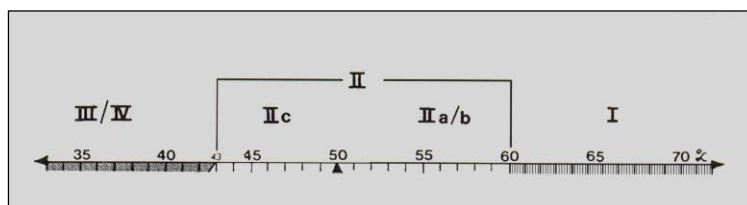
## 7. Fine Differentiation of Types/Sonometer

Arranging the alpha and beta values of all hip types results in a table called a Sonometer.

Using this table all stages of maturity, all Alpha and Beta angles, correlated to the age of the hip joint can be classified.

### 7.1 Alpha Value

If all Alpha values are plotted on a line, three large subdivisions can be differentiated.



- 1. Right section : ALPHA 60° or more ( $\Rightarrow$  60°) = type I
- 2. Middle section: ALPHA 43°-59° = type II
- 3. Left section : ALPHA less than 43° ( $<$  43°) = type III/IV

#### 7.1.1. Subdivision of Type II

All Type II hip joints are **centered** hips.

##### Type II c

ALPHA angle between 43° and 49°

This type means a severe bony socket dysplasia. It can be present at any age. If type II c is diagnosed, a thorough stress examination needs to be carried out to see if the joint is stable or unstable.

**TYPE II a**

Alpha between 50° and 59 ° (! >50° <59°)

Present in hip joints younger than 3 months

Type II-a joints can be subdivided into Type II a+ and Type II a-

**TYPE: II a +**

In the first three months after birth, the maturation of the hip joint is exponential - that is more rapid than linear growth. At birth, the minimum maturity of the ALPHA angle is 50°. If ALPHA is 50° at birth, then the hip joint can mature to Type I, Alpha 60, by the end of the third month.

Presuming the worst i.e. that the process of ossification of the hip joint between birth and the age of three months is linear, then the ossification of the hip joint, measured by the Alpha angle, should increase in a linear fashion from week to week. If the hip joint reaches the minimum expected maturity for a given age or exceeds it, then it is classified a Type II a+.

Type II a+ hips are physiologically immature but appropriate for age and are therefore “healthy” or normal.

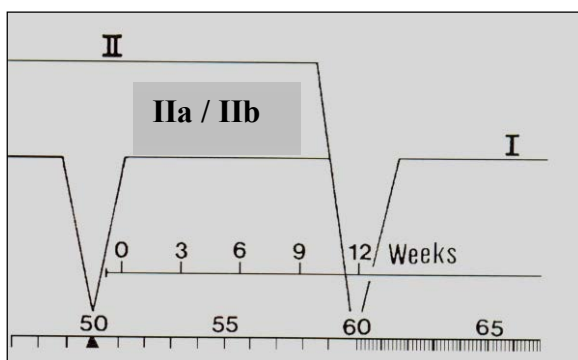
Type II a+ hips are present only before the end of the third month.

**Type II a -**

If the hip joint does not reach this minimum linear maturity then it is classified as type II a- and should be treated. Type II a- is a hip joint with delayed maturation (pathological) before the end of the third month. In practice it is not possible to differentiate between Type II a+ and Type II a- before the sixth week of life.

**Type II b**

The ALPHA value is between 50° and 59°, the hip joint is older than three months. This joint is consistent with a dysplastic joint.



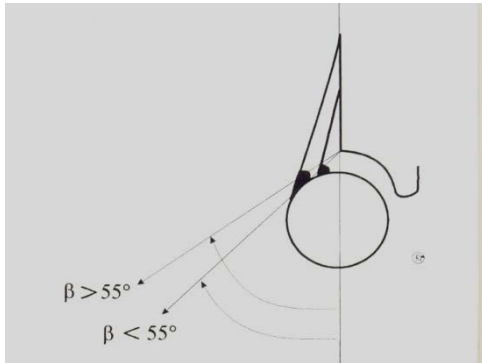
Correlation of Alpha angle with age in the first 12 weeks for differentiation of Type II a+ and Type II a-

**7.2 BETA Value**

Due to widespread normal variations of the cartilagenous roof and the more imprecise end points of the cartilage roof line, the BETA value is subject to greater statistical variation than the ALPHA value.

### 7.2.1 Type I a and Type I b

In mature hips with ALPHA > 60° so with identical bony coverage, the cartilagenous roof can vary greatly. On the one hand being wide and extending far over the femoral head with consequently a small BETA value or on the other hand being shorter so that the BETA value is higher.



Type I joints with BETA value of less than 55° are hip joints with a wide cartilagenous roof extending caudally far over the femoral head. These joints are classified as Type I a.  
 Type I hip joints with BETA value greater > than 55° are classified as I b. With our current level of knowledge, Type I a or I b joints are equally “good”.

Type I a and Type I b are variations of mature hips. Type I b hips are much more often than Type I a! Hypothesis: I a and I b may play a role in impingement or labral tears in young adults!?

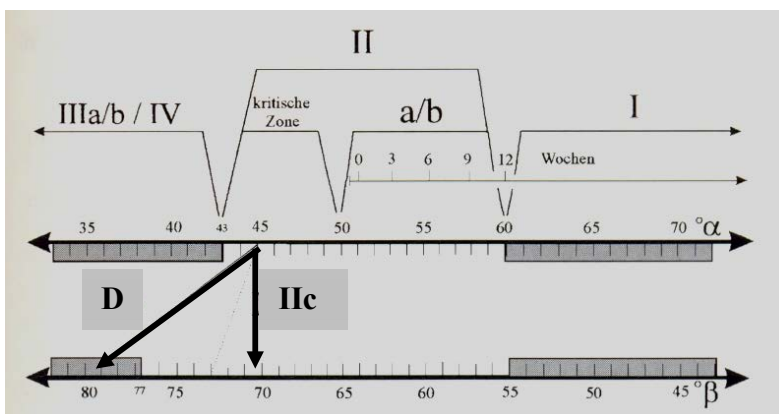
### 7.2.2 Type D

Hip joints in the II c range have such poor bony coverage that the femoral head may start to move out of the socket. The cranial displacement of the cartilagenous roof occurs without any change in the ALPHA value (the bony roof does not alter). However, due to the displacement of the cartilage, the BETA angle increases. If the BETA value of hip joints with ALPHA in the II c region (ALPHA between 43° and 49°) becomes greater than 77°, then these hips are classified as Type D.

A Type D hip is the first stage of decentring. These hip joints should not be classified as Type II D as all Type II joints are centered joints. Type D is classified as the first stage of a decentred hip.

**Type II c** ALPHA between 43° and 49°; BETA lesser than <77°

**Type D** ALPHA between 43° and 49°; BETA more than >77°

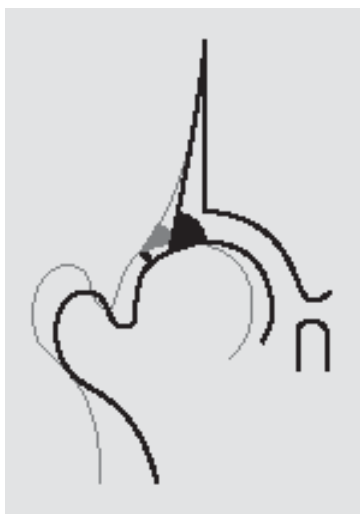


Sonometer showing diagram of the differences between Type II c and Type D

## 8. Elastic Whipping and Instability

### 8.1 Elastic Whipping (Physiological)

As the infant hip joint is not round but oval, sometimes described as “nut-shaped”, physiological incongruities occur with joint movement.



During rotation, adduction and abduction movements of adaption of the hyaline cartilage roof and acetabular labrum are seen.

This so called “elastic whipping” of the labrum and the cartilage roof can be observed even in fully mature hips. This must not be considered a sign of instability (Pathology).

The same “elastic whipping” can also be observed with a loose joint capsule.

### 8.2 Instability (Pathological)



Type II c joints are, as a rule, sonographically unstable. As a rule means that the majority of Type II c joints under pressure (stress examination) will become decentred (Type D). The term “sonographically unstable” means that this luxation can be observed on the sonogram or on the monitor. Unlike the subjectivity of the clinical physical examination, this observation can be made regardless of the skill and experience of the examiner.

The differentiation between stable and unstable is important for treatment. All decentred hips are inherently unstable.

#### Definition of Instability

If a Type II c hip joint can be altered under stress (pressure) to a Type D, then this joint is classified as Type II c unstable.

If a Type II c joint cannot be altered under stress to a Type D, then the final classification is Type II c stable.

**Important: All hip joints are classified without stress**

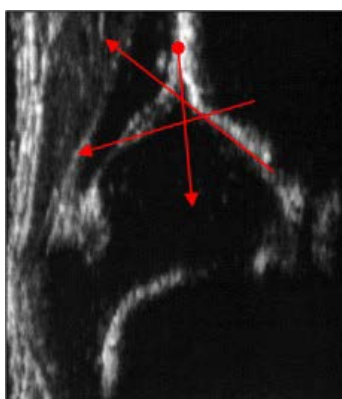
e.g., a Type III joint under pressure may be altered to a Type IV joint. Without stress, the joint is classified as Type III. The final type is therefore Type III.

Type D joints can of course also occur at rest without stress.

When does harmless elastic whipping change to pathological instability?

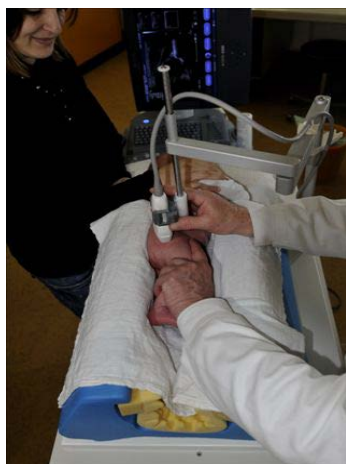Answer: As long as the ALPHA value is 50° or more i.e. a relatively good bony socket, then movement is harmless elastic whipping (even if the BETA value is greater than > 77°).

When the ALPHA value falls below 50°, that means a poor bony socket in the II c range, and the joint can be decentred under stress (BETA more > 77°), then this is pathological instability.



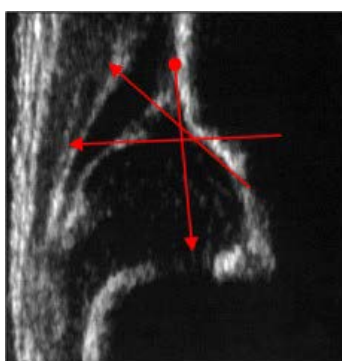
6 week old left hip joint

ALPHA 46 °  
 BETA 75°  
 Type II c  
 stable or unstable ?



Next step of examination:

Stress examination: The examiner gently grips the infants leg and presses dorso-cranially.



Same hip as above, however now after stress

ALPHA 46 °  
 BETA 92°  
 Type D

**Final classification: Type II c unstable**



## 9. Scanning Technique

The lower limb of the ilium, the correct sectional plane and the acetabular labrum must be shown simultaneously on the scan.

Each of these three structures is very small and is found in a space of only a few millimeters. The difficulty is that when one or two of these essential structures are displayed the third one is often missing. This problem can be solved by meticulous scanning technique in which speed plays an essential part. The scanning technique must be practiced on a doll and has nothing to do with experience or skill.

### 9.1 Cradle and Probe Guide System

In order to carry out quick and accurate scanning, a standard position for the infant and a standard scanning technique are needed. Used in combination with the cradle, the probe guide has proved to be very effective. Using both together enormously facilitates scanning the infant hip, reducing the scan time to a few seconds and considerably raising the standard of precision.

By correctly positioning the infant and using the probe guide system, tilting errors are virtually eliminated.

### 9.2 Preparation

**TIP:** Before the mother with the infant enters the examination room, all the patient details must be entered on the ultrasound machine. The mother and her companion are often agitated. Clear instructions help to minimize organisational chaos and transmit an air of calm and trustworthiness.

In the examination room a table must be available where the infant can be undressed. It is even better when there is also a nappy changing table outside the examination room where the infant can be undressed and, if necessary, cleaned

Documents, bottles, bags etc belonging to the patient can be deposited on the table in the examination room. This table can also be used for the clinical examination.

A further table is needed for the ultrasound examination. The height of this table is adjusted so that the examiner can place his forearms comfortably on the bolsters of the cradle. The examination should be carried out standing.

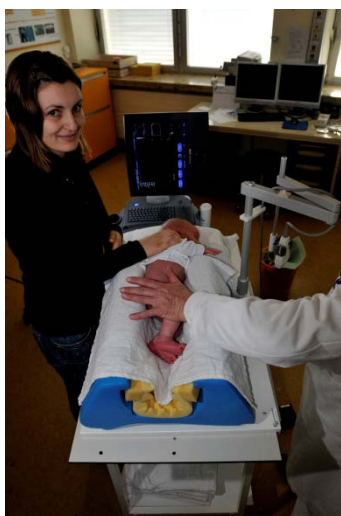### 9.3 Guiding the Mother

The examiner stands at the examination table, greets the mother, and shows her the preparation table. Here she can change the nappy and deposit her belongings.

The examiner then asks the mother to come to the far side of the examination table, takes the child from the mother and lays it on its side in the cradle with the right hip upwards. The mother should put her right hand on the shoulder of the child. Thus blocking her right hand and preventing her from pulling the child's leg.

### 9.4 Scanning Procedure

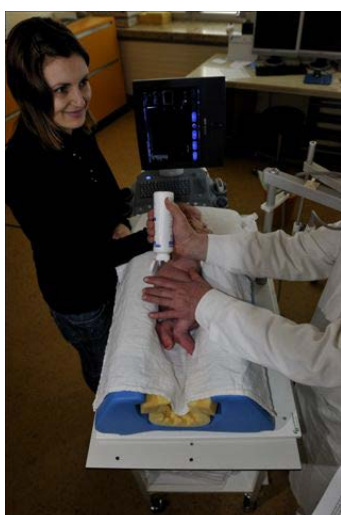#### 9.4.1 Right Hip Joint



##### Step 1

The examiner's left hand rotates the right leg slightly inward / *adduction*, so as to avoid the knee protruding above the cradle bolster.

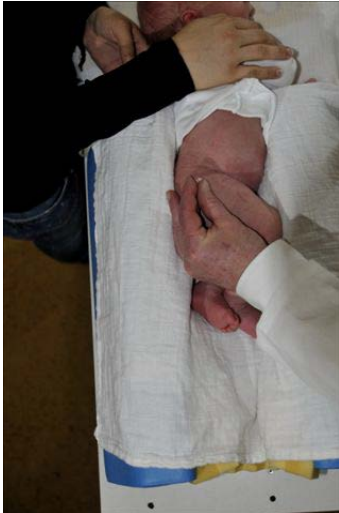The mother's hand is on the baby's right shoulder, not on the leg.



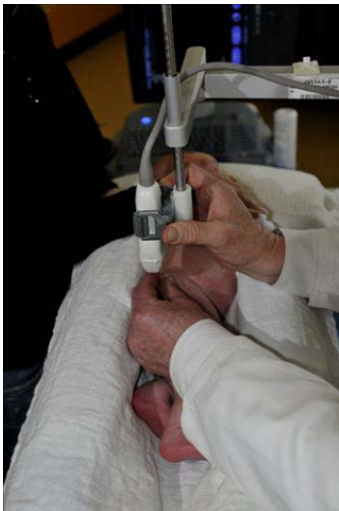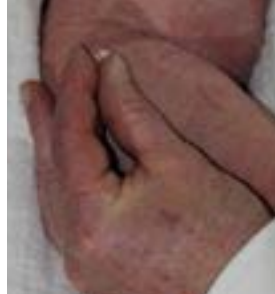##### Step 2

The examiner takes the gel tube with his/her right hand, places gel directly onto the baby's skin, and then returns the tube to the receptacle.

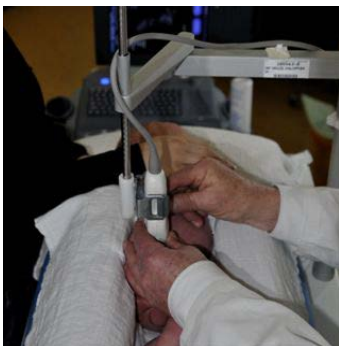Do not place the gel on the probe.

**Step 3**

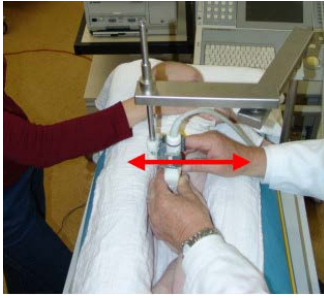
Thumb, index and middle finger are placed on the greater trochanter (fingers closed). Thumb in front, index and middle finger behind.

**Step 4**

Insert the probe from above.  
The probe pushes the fingers apart.

**Step 5**

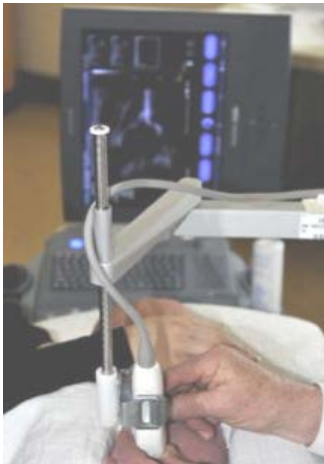Position of the probe:  
The probe is placed vertically on the hip joint parallel to the bolsters. Both of the examiner's forearms are supported by the bolsters of the cradle.



## Picture Presentation

### Step 1

The probe head is moved parallel to the bolsters, backwards and forwards over the greater trochanter. The examiner looks at the monitor. The movement is “forwards, backwards, forwards, backwards”, looking for the hip joint.

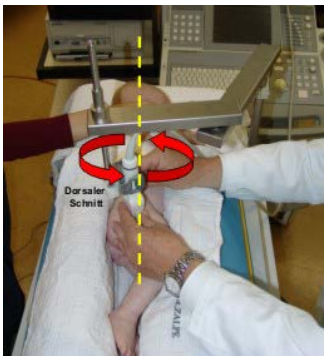

### Step 2

As soon as the hip joint is detected, the range of movements gets smaller in order to search for the lower limb of the ilium. As soon as the lower limb of the ilium is seen, then the image is frozen.

Movement : “Smaller- smaller- smaller-stop”

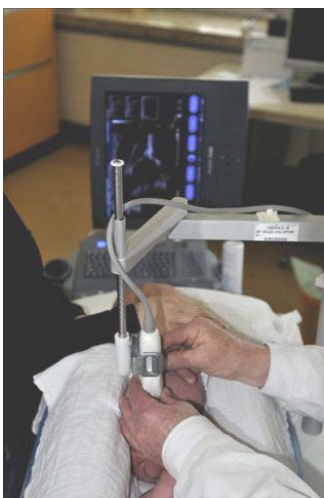It is important to concentrate exclusively on the lower limb of the ilium. The image must be frozen as soon as the lower limb appears.



### Step 3

The frozen sonogram allows the examiner to check the cross section of the bony roof. If the sectional plane is incorrect, the realignment must be done while looking at the probe.

Hint: Rotate the probe into what is estimated to be the correct plane and start again to look for the lower limb.

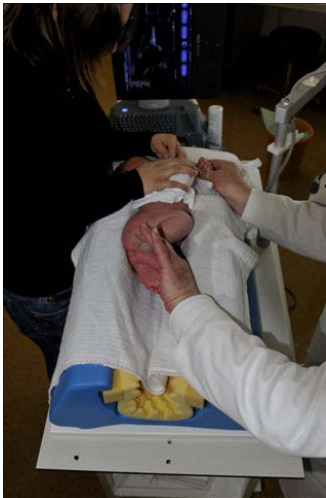

As soon as lower limb of the ilium and the sectional plane are correctly shown, the examination is finished since the acetabular labrum is displayed automatically using this technique.

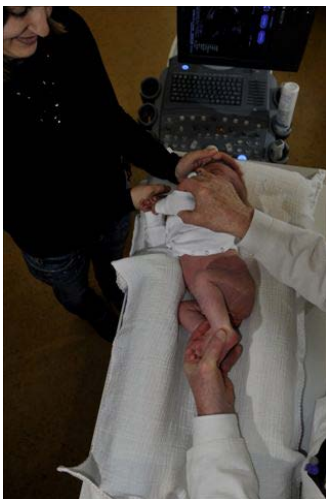Summing up the movements of the examination:

Forward-backward- forward-backward- smaller-smaller-smaller-stop. (lower limb is visible). If necessary rotate to correct the plane and start again with “forward-backward- forward-backward- smaller-smaller-smaller-stop”.

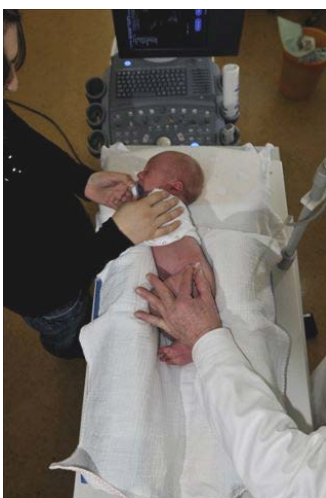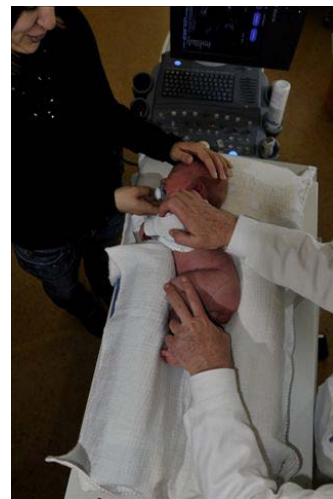### 9.4.2 Left Hip Joint



The examiner turns the baby in the cradle. He holds the baby's ankle joints with his pronated left hand between them; the right hand pulls carefully on the infant's left arm.

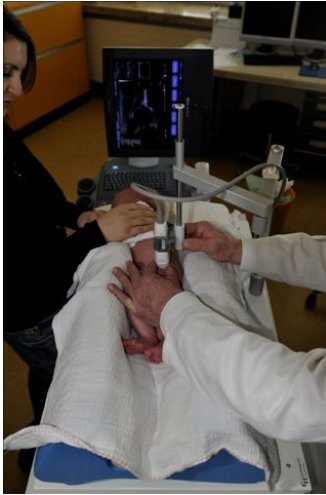

Thus rotation results and the infant can be turned over in the cradle.



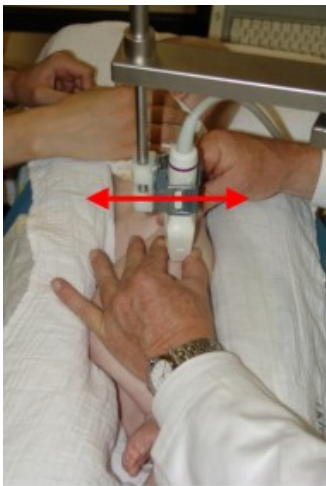
#### Step 1

The examiner's left hand is laid flat on the infant's hip joint.  
Thumb and index finger closed on the trochanter.



## Step 2

Examiner's lower arm lies gently on the infant's leg and is supported by the bolster of the cradle.



Examination manoeuvre as for the right hip.  
Forward-backward- forward-backward- smaller-smaller-smaller-stop.

If necessary: Rotate the probe; forward-backward-forward-backward- smaller-smaller-smaller-stop., again...

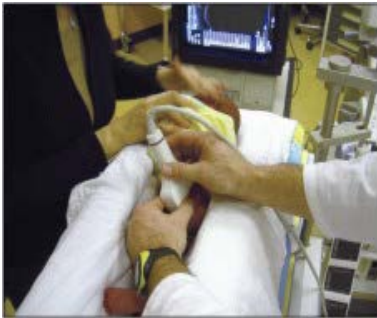

## 10. Tilting Errors

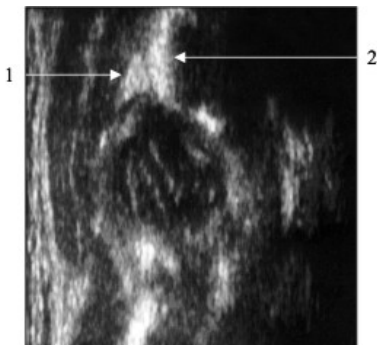
Due to the differing speed of sound in different tissues, the altered direction of the beam that occurs with tilting can cause substantial deviation of the beam resulting in erroneous images.

This occurs using sector scanners but can also be caused by tilting a linear probe. Tilting is the cause of much false diagnosis (over diagnosis).

### 10.1 Ventro dorsal tilting



With the beam in this direction a sonogram looking like a hip is produced. However, correct evaluation of the area of the bony rim is very difficult as the perichondrium and Ilium are widened and indistinct.

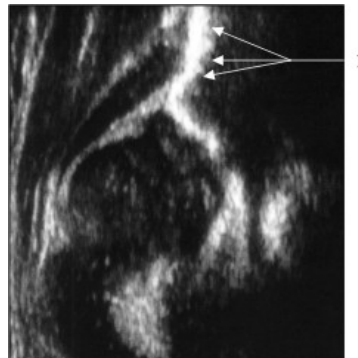
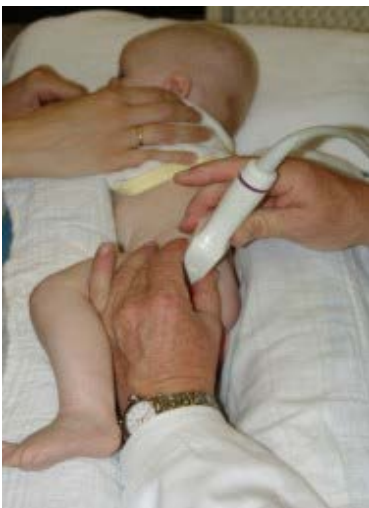
With expansion of the Ilium, the transition perichondrium - periostium is no longer visible. Anatomical identification is problematic so the base line is difficult to draw.

1. Widened perichondrium
2. Widened periostium

### 10.2. Dorso-Ventral Tilting

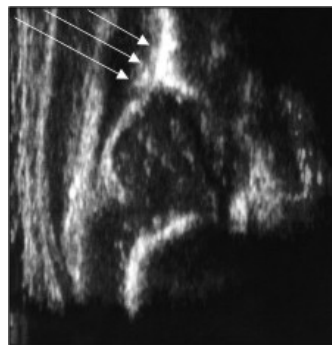
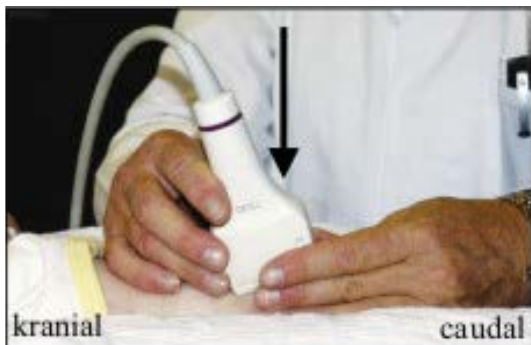With the beam in this direction, the cross section displayed looks like a dorsal section. The sound passes via the gluteal fossa into the hip joint.



1. Apparent dorsal cross section.

### 10.3 Cranio Caudal Tilting

With this beam direction, the lower limb of the Ilium is no longer visible because the beam is blocked by the iliac bone. This tilting error can often be seen in very small, thin newborn babies whose greater trochanter is very prominent.



Lower limb of Ilium missing.

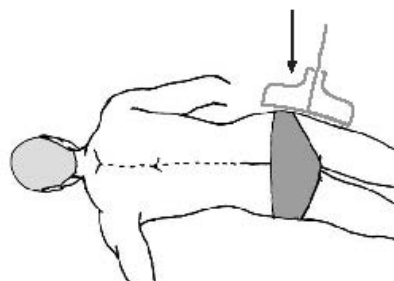
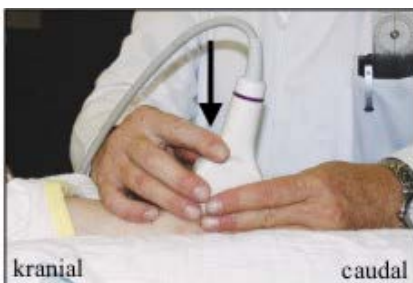Beam direction marked by arrows.

### 10.4 Caudo Cranial Tilting

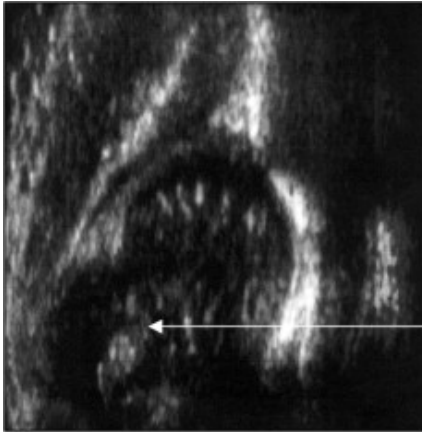
This most serious mistake is a combination of factors.

1. Due to differing speeds of sound in the hip joint and the skewed entrance of sound waves, diffraction and refraction occur.
2. With caudo-cranial tilting of the probe, the mid part of the bony roof looks like a posterior (dorsal) sectional plane. If one now turns the probe ventrally in order to correct the plane - in anatomical terms - one is now in the anterior (ventral) part of the bony roof.

This combination of mistakes may, in the worst case, lead to a normal hip joint appearing to be a pathological decentred hip, resulting in over diagnosis.

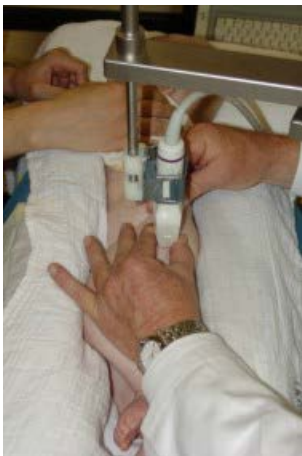



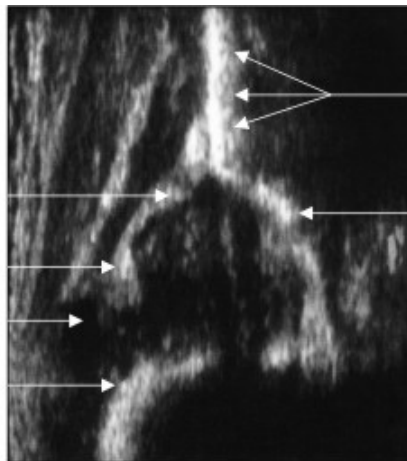


Seemingly pathological hip (same hip joint as below) *ChB* (1) missing or follows an atypical course.

The femoral head is “elongated”. Don't accept a sonogram without the chondr.oss.border (see checklist I).



Correct Scanning Technique.



- 1. Labrum
- 2. Synovial fold
- 3. Trochanter
- 4. ChB
- 5. Iliac bone silhouette
- 6. Lower limb of Ilium

It is, however, reassuring that:

In a sonogram a normal hip can be made to appear abnormal but an abnormal hip cannot be made to appear normal.

## 11. Appendix

### 11.1 Equipment Requirements

A linear transducer/probe 7.5 MHz or higher is essential for hip sonography.

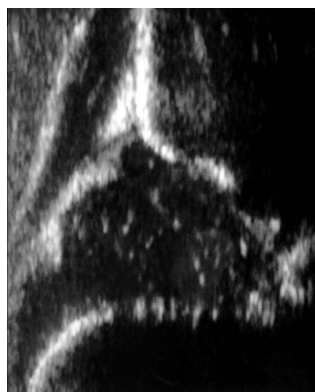A *trapezoidal* transducer (angle of deflection 10 ° max.) may be used but offers no advantage.

Sector or curved transducers lead to distortion with consequent false diagnosis and are therefore forbidden in hip sonography.

A cradle and a probe guide system are recommended for the examination.

### 11.2 Image Projection

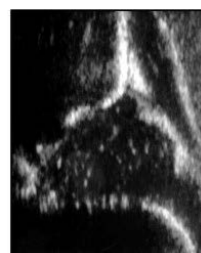
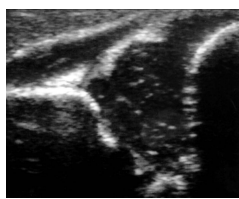
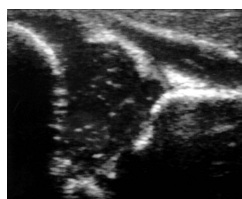
The infant hip joint should not be displayed as is usual in sonography with cranial left on the monitor but with cranial right. Whenever possible, it is strongly recommended that all sonograms are projected in such a way that they are similar to an AP projection of an X ray of the right hip.



### Sonographic Hip Projection

This projection is the easiest for our brain to interpret.

These projections are not recommended.



## 12. Recommendation for Treatment According to Sonographic Types

The best diagnosis is futile if not followed by appropriate treatment. A modern treatment is based according to the pathology of the joint. Because of the maturation curve of the hip joint, diagnosis and treatment (if necessary) should start within the first 6 weeks of life. The sonographic types are the mirror of the anatomical situation in the joint. Flexion ( $100^\circ$ ) Abduction (max.  $55^\circ$ ) (Flab-position), the so called "Human position" is essential in any way. In this position the caudo-cranial shearing forces, which are responsible for the deformation of the cartilage roof, are stopped and the cartilage roof can recover.

### RESULT = DIAGNOSIS + TREATMENT

**Type I :** mature joint, no control, no treatment

**Type IIa:** (+) : according to the age, only control when it is a "risk baby".

(-) : treatment in flexion/abduction device (Flab)

**Type IIb:** Dysplastic joint older than 3 months: flexion/abduction device

**Type IIc:** - stabil: Heavy dysplasia at any age: Flab immediately

- unstabil: Pavlik recommended

**Type D/III/IV:** decentred joints: e.g. Pavlik, overhead traction, eventual cast after reduction.

## 13. Recommended Literature

### Rec.References:

- 1.Graf R, Baumgartner F, Lercher K, Scott S, Benaroya A, (2006) : Hip Sonography. Diagnosis and Managment of Infant Hip Dysplasia. Springer ISBN 3-540-30957-8
- 2.Graf R, Mohajer M, Plattner F: (2013) Hip sonography update. Quality-mangment,catastropes-tips and tricks. Med Ultrason 15,4: 299-303
- 3.Tschauner C Fürnrath F, Radl R, Berghold A, Schweintzger G. (2012) Improved therapeutic outcome of decentred hip joints by early sonographic diagnosis using the Graf technique. OUB 1: 390-393
4. Thallinger Ch, Posposchill R, Ganger R, Radler C, Krall C, Grill F. (2014)

Long Term results of a national wide general ultrasound screening system for developmental disorders of the hip: the Austrian hip screening program. J Child Orthop 8:3-10

### Positioning device and probe guide system:

° info@hirschbeck.eu

° aida.shuku@arcor.de

# ESSENTIALS OF INFANT HIP SONOGRAPHY

## According to GRAF

